

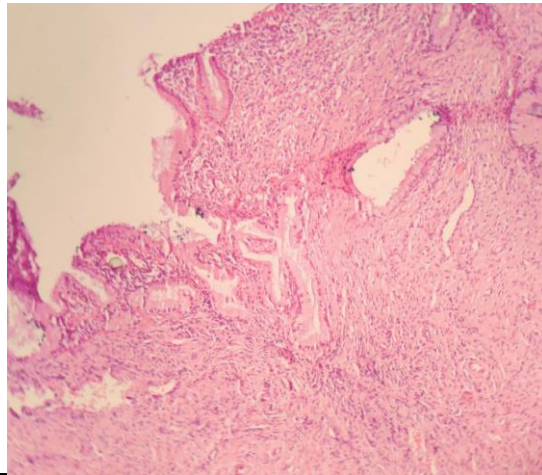
<b>Patient Name</b>	<b>Ms. PUSHPA</b>	<b>Client Name</b>	IRCC Hospital, Panchkula	<b>Specimen Received</b>	06-Feb-2020
<b>Age/Sex</b>	43 Years/Female			<b>Specimen Type</b>	Tissue
<b>Patient ID</b>	012002090047			<b>Collection Date</b>	09-Feb-2020
<b>Specimen ID</b>	MOLQ/B-274/20			<b>Report Date</b>	12-Feb-2020

## SURGICAL PATHOLOGY REPORT

### Cervical Biopsy

#### DIAGNOSIS

### CHRONIC CERVICITIS



#### SPECIMEN

Cervical Biopsy

#### GROSS

Received multiple grayish white tissue piece.


#### Microscopy

1. Section examined shows squamous lining epithelium with round to oval nucleus. Presence of endocervical glands with round to oval nucleus.
2. Stroma shows mononuclear inflammatory cells.
3. No granuloma seen. No malignant cells seen.

**Note :** All biopsy specimen will be stored for 15 (fifteen) days, block and slides for 5 (five) years only from the time of receipt at the laboratory. No request, for any of the above, will be entertained after the due date.

#### Reference

- i) Rosai and Ackerman's Surgical Pathology.
- ii) Modern Surgical Pathology.



**Gulshan Yadav, MD**  
Consultant Pathologist