

Patient Name AKBAR
Age/Sex 40 YRS/M
Patient ID 012002060268
Specimen ID MOLQ/B-244-20

Client Name Family Hospital and
Surgical Centre

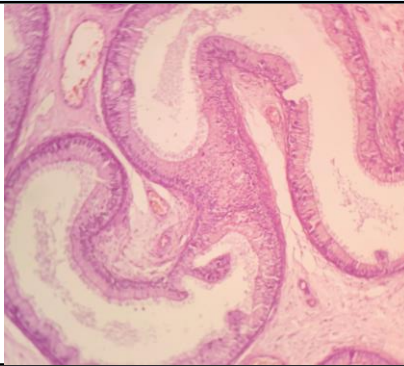
Specimen Received 06-Feb-2020
Specimen Type Tissue
Collection Date 06-Feb-2020
Report Date 12-Feb-2020

SURGICAL PATHOLOGY REPORT

Epididymal Cyst

DIAGNOSIS

Epididymal Cyst



SPECIMEN

Epididymal Cyst

GROSS

Received 4.6x4.3 cm cystic tissue piece. Cut section shows clear fluid.

Microscopy

Section examined shows lining epithelium with small round nuclues, fibrocollagneosut sittues with large number of blood vessels.

No granuloma seen. No malignant cells seen.

Note : All biopsy specimen will be stored for 15 (fifteen)days, block and slides for 5(five) years only from the time of receipt at the laboratory. No request ,for any of the above ,will be entertained after the due date.

Reference

- i) Rosai and Ackerman's Surgical Pathology.
- ii) Modern Surgical Pathology.



Gulshan Yadav, MD
Consultant Pathologist