

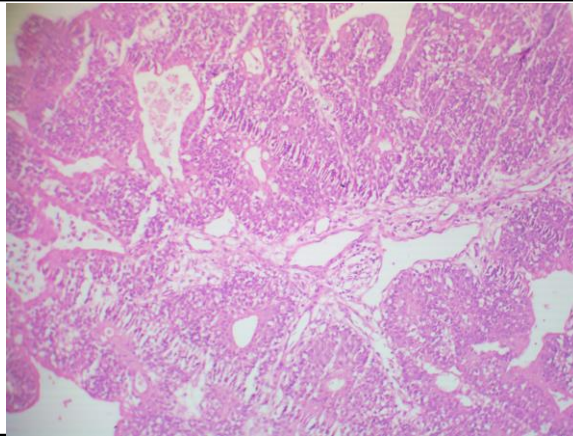
Patient Name	Mrs. GANGA DEVI 47834	Specimen Received	05-Feb-2019
Age/Sex	60 Years/Female	Specimen Type	Tissue
Patient ID	012002050315	Client Name	Pushpanjali
Specimen ID	MOLQ/B-232/20	Hospital (Rewari)	Hospital (Rewari)
		Collection Date	05-Feb-2019
		Report Date	12-Feb-2019

SURGICAL PATHOLOGY REPORT

Bladder Tumor

DIAGNOSIS

LOW GRADE UROTHELIAL CARCINOMA



SPECIMEN

Bladder Tumor

Microscopy

Histologic Type:

Tumor Configuration:

Adequacy of Material for Determining Muscularis Propria Invasion.

Muscularis Propria Invasion:

Lymph vascular Invasion:

Microscopic extent of tumor:

GROSS

Received multiple grayish white tissue piece. E/A

Urothelial (Transitional Cell) Carcinoma.

Low Grade.

Solid / Nodule.

Not Invaded.

Not Invaded.

Tumor invaded subepithelial connective tissue (lamina propria).

Muscularis propria is not invaded.

Detrusor muscle not invaded

Note : All biopsy specimen will be stored for 15 (fifteen)days, block and slides for 5(five) years only from the time of receipt at the laboratory. No request ,for any of the above ,will be entertained after the due date.

Reference

- i) Rosai and Ackerman's Surgical Pathology.
- ii) Modern Surgical Pathology.

Gulshan Yadav, MD
Consultant Pathologist