

Patient Name ABHISHEK
Age/Sex 04 YRS/M
Patient ID 012002050282
Specimen ID MOLQ/B-231-20

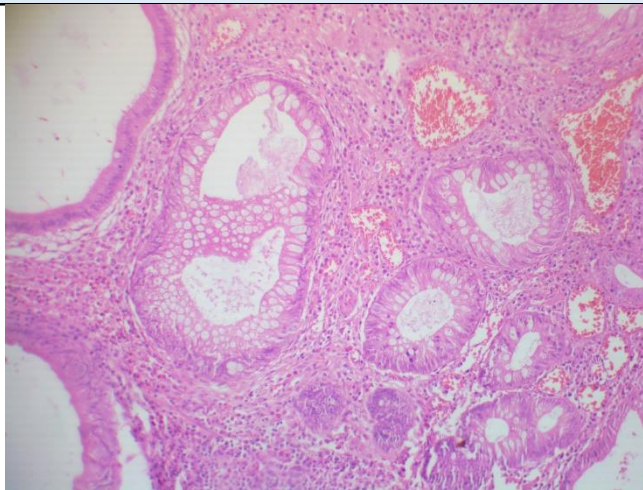
Client Name Umkal Hospital

Specimen Received 05-Feb-2020
Specimen Type Tissue
Collection Date 05-Feb-2020
Report Date 12-Feb-2020

SURGICAL PATHOLOGY REPORT Rectal Polyp

DIAGNOSIS

JUVENILE RETENTION POLYP



SPECIMEN

Rectal Polyp

GROSS

Received 2X2 cm grayish white tissue piece.

Microscopy

Section examined shows submucosal glands with columnar lining epithelium with round to oval nucleus with mild anisonucleosis and inflammatory cells (predominantly composed of lymphocytes and polymorphs). No granuloma seen. No malignant cells seen.

Note : All biopsy specimen will be stored for 15 (fifteen) days, block and slides for 5 (five) years only from the time of receipt at the laboratory. No request, for any of the above, will be entertained after the due date.

Reference

- i) Rosai and Ackerman's Surgical Pathology.
- ii) Modern Surgical Pathology.

Gulshan Yadav, MD
Consultant Pathologist