

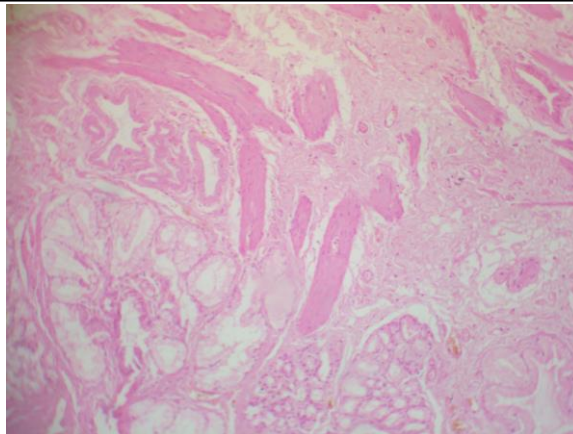
<b>Patient Name</b>	Mrs. SHAZADA W/O M YOUSUF	<b>Client Name</b>	Apex Medicare, Jammu & Kashmir	<b>Specimen Received</b>	03-Feb-2020
<b>Age/Sex</b>	45YRS/F			<b>Specimen Type</b>	Tissue
<b>Patient ID</b>	012002030061			<b>Collection Date</b>	03-Feb-2020
<b>Specimen ID</b>	MOLQ/B-222-20			<b>Report Date</b>	07-Feb-2020

## SURGICAL PATHOLOGY REPORT

### Gall Bladder

#### DIAGNOSIS

### CHOLECYSTITIS AND CHOLELITHIASIS.



**SPECIMEN**  
Gall Bladder

#### **GROSS**

Received 5.8x2.9 cm long gall bladder. Cut section shows stones. Wall Thickness 0.2 mm.

#### **Microscopy**

Section examined shows ulcerative mucosa and Rokitansky-Aschoff sinus (irregularly shaped tubular structures lined by cuboidal lining epithelium with round to oval nucleus) with fibrocollagenous tissue and inflammatory cells (lymphocytes).

**Note :** All biopsy specimen will be stored for 15 (fifteen) days, block and slides for 5 (five) years only from the time of receipt at the laboratory. No request, for any of the above, will be entertained after the due date.

#### **Reference**

- i) Rosai and Ackerman's Surgical Pathology.
- ii) Modern Surgical Pathology.

**Gulshan Yadav, MD**  
Consultant Pathologist