

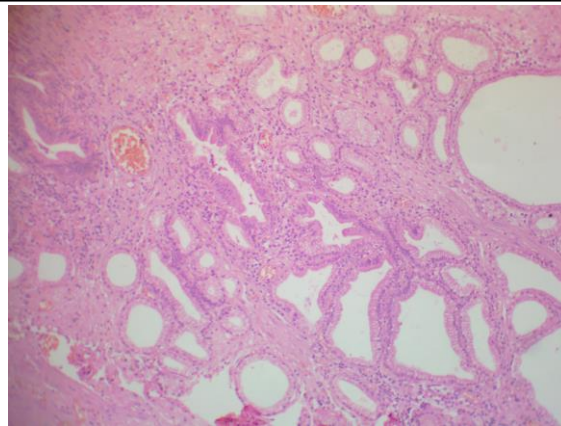
Patient Name	Mrs. HASEENA W/O AB SALAM	Client Name	Apex Medicare, Jammu & Kashmir	Specimen Received	03-Feb-2020
Age/Sex	55YRS/F			Specimen Type	Tissue
Patient ID	012002030060			Collection Date	03-Feb-2020
Specimen ID	MOLQ/B-221-20			Report Date	07-Feb-2020

SURGICAL PATHOLOGY REPORT

Gall Bladder

DIAGNOSIS

CHOLECYSTITIS



SPECIMEN
Gall Bladder

GROSS

Received 6.3x2.9 cm long gall bladder without stones.
Wall Thickness 0.4 mm.

Microscopy

Section examined shows ulcerative mucosa and Rokitansky-Aschoff sinus (irregularly shaped tubular structures lined by cuboidal lining epithelium with round to oval nucleus) with fibrocollagenous tissue and inflammatory cells (lymphocytes).

Note : All biopsy specimen will be stored for 15 (fifteen) days, block and slides for 5 (five) years only from the time of receipt at the laboratory. No request, for any of the above, will be entertained after the due date.

Reference

- i) Rosai and Ackerman's Surgical Pathology.
- ii) Modern Surgical Pathology.

Gulshan Yadav, MD
Consultant Pathologist