

Patient Name Mrs. NAZIRA W/O SHAKEEL AH
Age/Sex 32YRS/F
Patient ID 012002030057
Specimen ID MOLQ/B-218-20

Client Name Apex Medicare,
Jammu & Kashmir

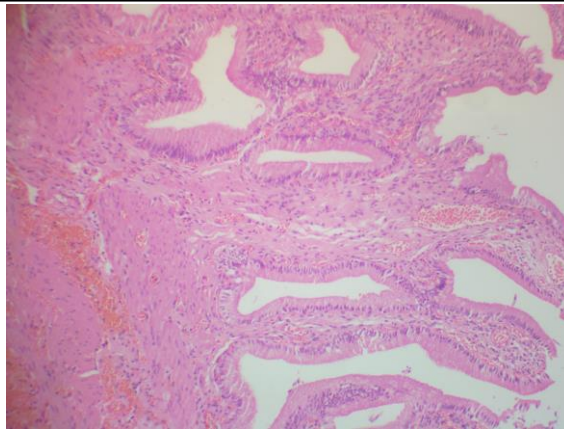
Specimen Received 03-Feb-2020
Specimen Type Tissue
Collection Date 03-Feb-2020
Report Date 07-Feb-2020

SURGICAL PATHOLOGY REPORT

Gall Bladder

DIAGNOSIS

CHOLECYSTITIS AND CHOLELITHIASIS.



SPECIMEN
Gall Bladder

GROSS

Received 5.9x2.9 cm long gall bladder already cut open with stones. Wall Thickness 0.3 mm.

Microscopy

Section examined shows ulcerative mucosa and Rokitansky-Aschoff sinuses (irregularly shaped tubular structures lined by cuboidal lining epithelium with round to oval nucleus) with fibrocollagenous tissue and inflammatory cells (lymphocytes).

Note : All biopsy specimen will be stored for 15 (fifteen) days, block and slides for 5 (five) years only from the time of receipt at the laboratory. No request, for any of the above, will be entertained after the due date.

Reference

- i) Rosai and Ackerman's Surgical Pathology.
- ii) Modern Surgical Pathology.

Gulshan Yadav, MD
Consultant Pathologist