

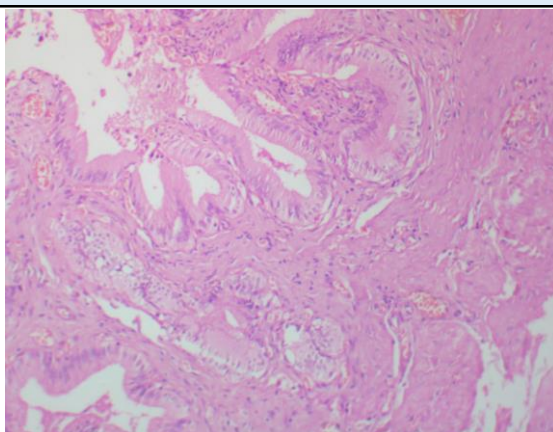
Patient Name	Mrs. SHAZIA JAN W/O IRSHAD AH	Specimen Received	03-Feb-2020
Age/Sex	30YRS/F	Specimen Type	Tissue
Patient ID	012002030055	Collection Date	03-Feb-2020
Specimen ID	MOLQ/B-216-20	Report Date	07-Feb-2020
	Client Name Apex Medicare, Jammu & Kashmir		

SURGICAL PATHOLOGY REPORT

Gall Bladder

DIAGNOSIS

CHOLECYSTITIS AND CHOLELITHIASIS.



GROSS

Received 7.8x2.9 cm long gall bladder already cut open with multiple stones.

SPECIMEN

Gall Bladder

Microscopy

Section examined shows ulcerative mucosa and Rokitansky-Aschoff sinuses (irregularly shaped tubular structures lined by cuboidal lining epithelium with round to oval nucleus) with fibrocollagenous tissue and inflammatory cells (lymphocytes).

Note : All biopsy specimen will be stored for 15 (fifteen) days, block and slides for 5 (five) years only from the time of receipt at the laboratory. No request, for any of the above, will be entertained after the due date.

Reference

- i) Rosai and Ackerman's Surgical Pathology.
- ii) Modern Surgical Pathology.

Gulshan Yadav, MD
Consultant Pathologist