

Patient Name Mrs. UNNSI
Age/Sex 62YRS/F
Patient ID 012002010135
Specimen ID MOLQ/B-209-20

Client Name Family Hospital and
Surgical Centre

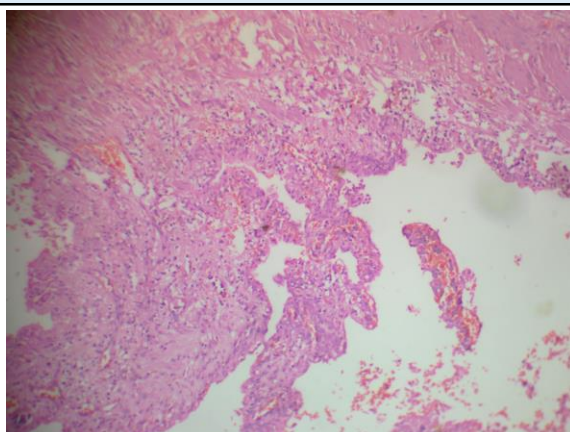
Specimen Received 1-Feb-2020
Specimen Type Tissue
Collection Date 1-Feb-2020
Report Date 06-Feb-2020

SURGICAL PATHOLOGY REPORT

Gall Bladder

DIAGNOSIS

CHOLECYSTITIS



SPECIMEN

Gall Bladder

GROSS

Received 9x4 cm long gall bladder already cut open. Wall thickness 11.0 mm.


Microscopy

Section examined shows ulcerative mucosa and Rokitansky-Aschoff sinus (irregularly shaped tubular structures lined by cuboidal lining epithelium with round to oval nucleus) with fibrocollagenous tissue and inflammatory cells (lymphocytes).

Note : All biopsy specimen will be stored for 15 (fifteen) days, block and slides for 5 (five) years only from the time of receipt at the laboratory. No request, for any of the above, will be entertained after the due date.

Reference

- i) Rosai and Ackerman's Surgical Pathology.
- ii) Modern Surgical Pathology.


Gulshan Tanna, MD
Consultant Pathologist