

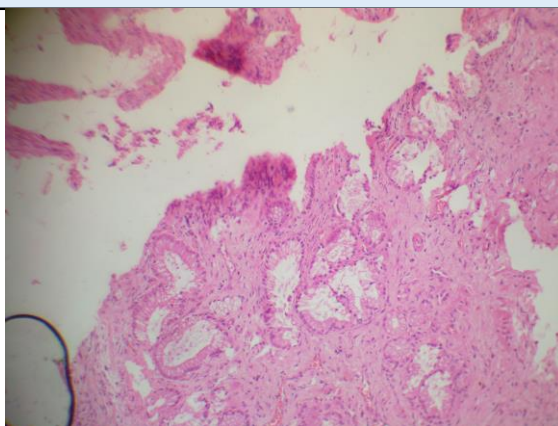
Patient Name	Mrs. LAXMI	Client Name	Family Hospital and Surgical Centre	Specimen Received	01-Feb-2020
Age/Sex	50YRS/F			Specimen Type	Tissue
Patient ID	012002010134			Collection Date	01-Feb-2020
Specimen ID	MOLQ/B-208-20			Report Date	06-Feb-2020

SURGICAL PATHOLOGY REPORT

Gall Bladder

DIAGNOSIS

CHOLECYSTITIS AND CHOLELITHIASIS.



SPECIMEN

Gall Bladder

GROSS

Received 7.2x3.1 cm long gall bladder. Cut section shows stones. Wall Thickness 0.6 mm.

Microscopy

Section examined shows ulcerative mucosa and Rokitansky-Aschoff sinus (irregularly shaped tubular structures lined by cuboidal lining epithelium with round to oval nucleus) with fibrocollagenous tissue and inflammatory cells (lymphocytes).

Note : All biopsy specimen will be stored for 15 (fifteen) days, block and slides for 5 (five) years only from the time of receipt at the laboratory. No request, for any of the above, will be entertained after the due date.

Reference

- i) Rosai and Ackerman's Surgical Pathology.
- ii) Modern Surgical Pathology.

Gulshan TAAAV, MD
Consultant Pathologist