

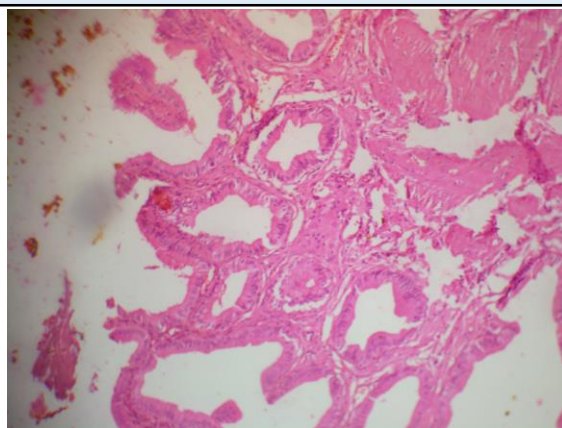
Patient Name	Ms. SAMY JAN	Client Name	A-One Collection Centre, Jammu & Kashmir	Specimen Received	31-Jan-2020
Age/Sex	...YRS/F			Specimen Type	Tissue
Patient ID	042001310019			Collection Date	31-Jan-2020
Specimen ID	MOLQ/B-204-20			Report Date	04-Feb-2020

SURGICAL PATHOLOGY REPORT

Gall Bladder

DIAGNOSIS

CHOLECYSTITIS AND CHOLELITHIASIS.



SPECIMEN

Gall Bladder

GROSS

Received 6.1x2.9 cm long gall bladder. Cut section shows tiny stones.

Microscopy

Section examined shows ulcerative mucosa and Rokitansky-Aschoff sinus (irregularly shaped tubular structures lined by cuboidal lining epithelium with round to oval nucleus) with fibrocollagenous tissue and inflammatory cells (lymphocytes).

Note : All biopsy specimen will be stored for 15 (fifteen) days, block and slides for 5 (five) years only from the time of receipt at the laboratory. No request, for any of the above, will be entertained after the due date.

Reference

- i) Rosai and Ackerman's Surgical Pathology.
- ii) Modern Surgical Pathology.

Gulshan Yadav, MD
Consultant Pathologist