

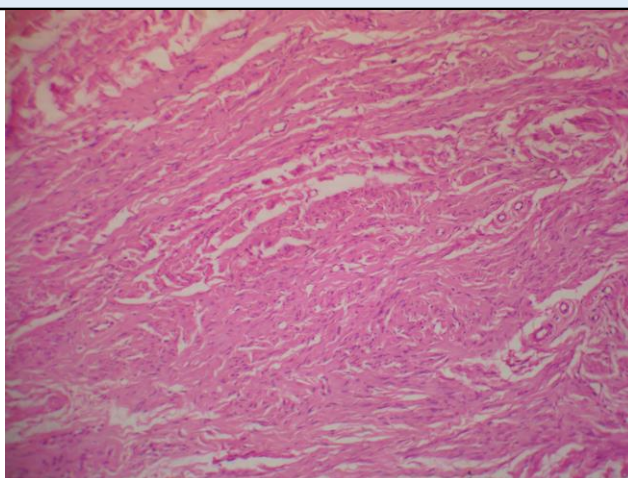
<b>Patient Name</b>	Ms. HAMEEDA KHREW	<b>Client Name</b>	A-One Collection Centre, Jammu & Kashmir	<b>Specimen Received</b>	29-Jan-2020
<b>Age/Sex</b>	35YRS/F			<b>Specimen Type</b>	Tissue
<b>Patient ID</b>	042001290006			<b>Collection Date</b>	29-Jan-2020
<b>Specimen ID</b>	MOLQ/B-185-20			<b>Report Date</b>	03-Feb-2020

## SURGICAL PATHOLOGY REPORT

### Uterus with Cervix

#### DIAGNOSIS

#### LEIOMYOMA



#### SPECIMEN

Uterus with Cervix

#### GROSS

Received 9x7.6 cm uterus with cervix with bilateral adnexa. Ovary size 6x5 cm, 2x2 cm. Cut section shows 1.5x1 cm fibroid.

#### Microscopy

Section examined shows

- 1) Endometrium with proliferative phase
- 2) Myometrium with muscle bundles
- 3) Cervix with mononuclear inflammatory cells
- 4) Ovary with dermoid cyst (cheesy material and hair) and tube unremarkable
- 5) Other ovary with luteal cyst and tube unremarkable
- 6) Fibroid with interlacing muscle bundles.

**Note :** All biopsy specimen will be stored for 15 (fifteen) days, block and slides for 5 (five) years only from the time of receipt at the laboratory. No request, for any of the above, will be entertained after the due date.

#### Reference

- i) Rosai and Ackerman's Surgical Pathology.
- ii) Modern Surgical Pathology.

**Gulshan Yadav, MD**  
**Consultant Pathologist**

*Report generated at MolQ Laboratory, Gurgaon*