

**Patient Name** Ms. ANGURI DEVI  
**Age/Sex** 50YRS/F  
**Patient ID** 012001300244  
**Specimen ID** MOLQ/B-192-20

**Client Name** S. M. Diagnostics,  
Kaithal

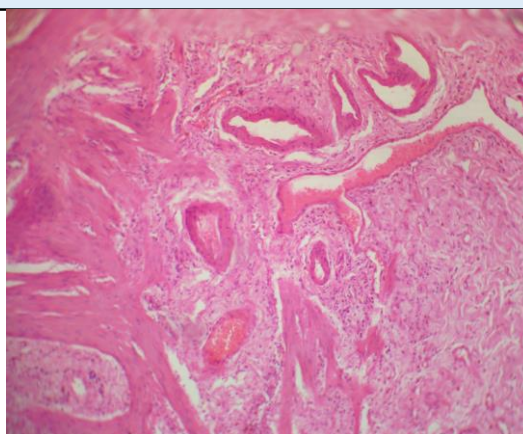
**Specimen Received** 30-Jan-2020  
**Specimen Type** Tissue  
**Collection Date** 30-Jan-2020  
**Report Date** 04-Feb-2020

## SURGICAL PATHOLOGY REPORT

### Gall Bladder

#### DIAGNOSIS

### CHOLECYSTITIS AND CHOLELITHIASIS.



#### SPECIMEN

Gall Bladder

#### GROSS

Received 6.5x2.9 cm long gall bladder. Cut section shows stones. Wall Thickness 0.2 mm.

#### Microscopy

Section examined shows ulcerative mucosa and Rokitansky-Aschoff sinus (irregularly shaped tubular structures lined by cuboidal lining epithelium with round to oval nucleus) with fibrocollagenous tissue and inflammatory cells (lymphocytes).

**Note :** All biopsy specimen will be stored for 15 (fifteen) days, block and slides for 5 (five) years only from the time of receipt at the laboratory. No request, for any of the above, will be entertained after the due date.

#### Reference

- i) Rosai and Ackerman's Surgical Pathology.
- ii) Modern Surgical Pathology.

**Gulshan Yadav, MD**  
Consultant Pathologist