

Patient Name Mr. OM PRAKASH
Age/Sex 30YRS/F
Patient ID 012001300238
Specimen ID MOLQ/B-191-2020

Client Name Vedic Hospital

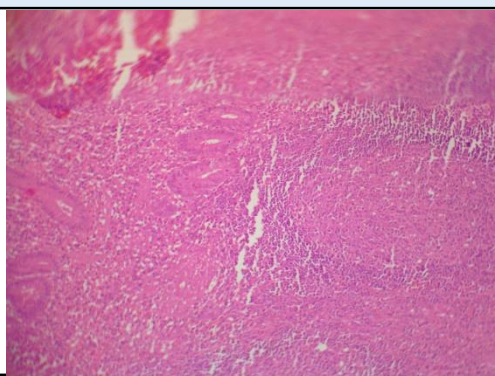
Specimen Received 30-Jan-2020
Specimen Type Tissue
Collection Date 30-Jan-2020
Report Date 04-Feb-2020

SURGICAL PATHOLOGY REPORT

Acute Appendix

DIAGNOSIS

ACUTE APPENDICITIS



SPECIMEN

Acute Appendix

GROSS

Received 5.6x3.5 cm long appendix with mesoappendix.
Cut section shows feco-lith.

Microscopy

Section examined shows from appendix lymphoid follicles with ulcerative mucosa. Deeper tissue shows inflammatory cells (polymorphs and lymphocytes). No granuloma seen. No malignant cells seen.

Section examined from mesoappendix shows mature adipose cells. No granuloma seen. No malignant cells seen.

Note : All biopsy specimen will be stored for 15 (fifteen)days, block and slides for 5(five) years only from the time of receipt at the laboratory. No request ,for any of the above ,will be entertained after the due date.

Reference

- Rosai and Ackerman's Surgical Pathology.
- Modern Surgical Pathology.



Gulshan Yadav, MD
Consultant Pathologist