

Patient Name Ms. PUSPHA
Age/Sex 45 Years/Female
Patient ID 012001300026
Specimen ID Molq/B-178-20

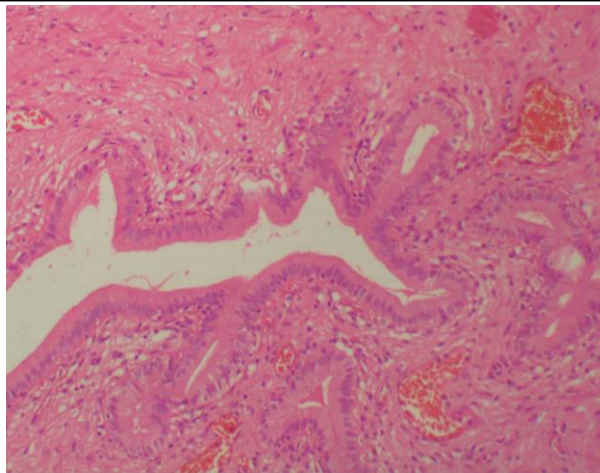
Specimen Received 30-Jan-2020
Specimen Type Tissue
Collection Date 30-Jan-2020
Report Date 03-Feb-2020

SURGICAL PATHOLOGY REPORT

Gall Bladder

DIAGNOSIS

CHOLECYSTITIS



SPECIMEN

Gall Bladder

GROSS

Received 3.3x2.9 cm long gall bladder without stones. Wall Thickness 0.3 mm.

Microscopy

1. Section examined shows ulcerative mucosa and Rokitansky-Aschoff sinuses (irregularly shaped tubular structures lined by cuboidal lining epithelium with round to oval nucleus) with fibrocollagenous tissue and inflammatory cells (lymphocytes).

Note : All biopsy specimen will be stored for 15 (fifteen) days, block and slides for 5 (five) years only from the time of receipt at the laboratory. No request, for any of the above, will be entertained after the due date.

Reference

- i) Rosai and Ackerman's Surgical Pathology.
- ii) Modern Surgical Pathology.