

Patient Name Mrs. KANTA
Age/Sex 36YRS/F
Patient ID 012001290320
Specimen ID MOLQ/B-180-20

Client Name Prakash Hospital

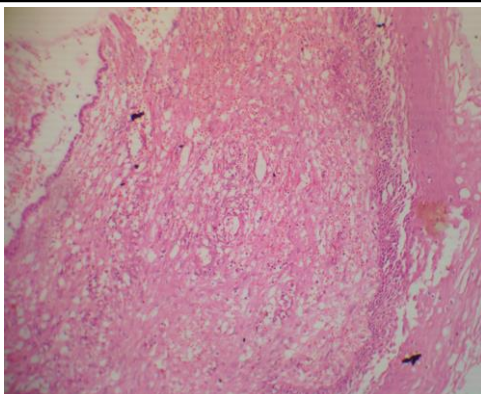
Specimen Received 29-Jan-2020
Specimen Type Tissue
Collection Date 29-Jan-2020
Report Date 04-Feb-2020

SURGICAL PATHOLOGY REPORT

Hypertrophic Growth Cervix

DIAGNOSIS

CHRONIC CERVICITIS
ADVISED: FOLLOW UP.



SPECIMEN

Hypertrophic Growth Cervix

GROSS

Received tiny grayish white tissue piece.

Microscopy


Section examined shows squamous lining epithelium with round to oval nucleus. Deeper tissue shows fibrocollagenous tissue, blood vessels and few inflammatory cells.

No malignant cells seen in sample received.

Note : All biopsy specimen will be stored for 15 (fifteen) days, block and slides for 5 (five) years only from the time of receipt at the laboratory. No request, for any of the above, will be entertained after the due date.

Reference

- i) Rosai and Ackerman's Surgical Pathology.
- ii) Modern Surgical Pathology.



Gulshan Yadav, MD
Consultant Pathologist