

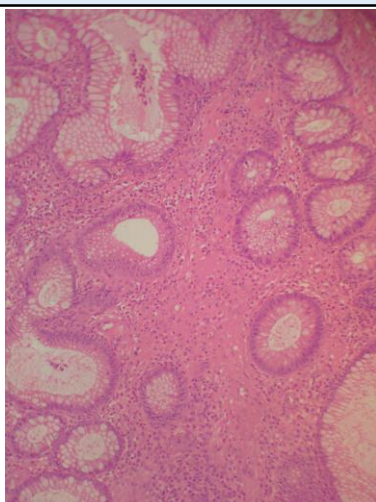
Patient Name	Mr. SHRI BHAGWAN	Client Name	Pushpanjali Hospital (Rewari)	Specimen Received	25/01/2020
Age/Sex	65YRS/M			Specimen Type	Tissue
Patient ID	012001250324			Collection Date	25/01/2020
Specimen ID	MOLQ/B-160-20			Report Date	29/01/2020

SURGICAL PATHOLOGY REPORT

TURP Chips

DIAGNOSIS

BENIGN PROSTATIC HYPERPLASIA



SPECIMEN

TURP Chips

GROSS

Received multiple grayish white tissue piece, 4x4 cm in aggregate.

Microscopy

Section examined shows bilayered prostatic glands with columnar lining epithelium and with small round to oval nucleus surrounded by large number of fibrocollagenous tissue and mononuclear inflammatory cell.

No granuloma seen. No malignant cells seen.

Note : All biopsy specimen will be stored for 15 (fifteen)days, block and slides for 5(five) years only from the time of receipt at the laboratory. No request ,for any of the above ,will be entertained after the due date.

Reference

- i) Rosai and Ackerman's Surgical Pathology.
- ii) Modern Surgical Pathology.

Gulshan Yadav, MD
Consultant Pathologist