

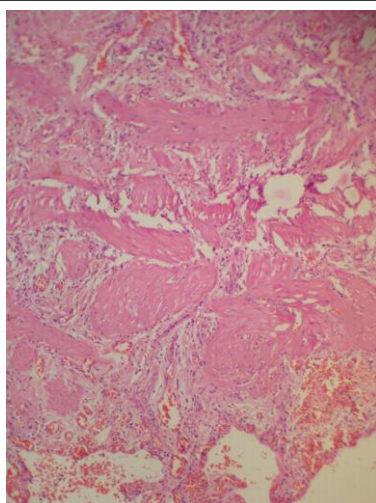
Patient Name	Baby. LAXMI	Client Name	Goyal Nursing Home, Palwal	Specimen Received	25/01/2020
Age/Sex	8YRS/F			Specimen Type	Tissue
Patient ID	012001250280			Collection Date	25/01/2020
Specimen ID	MOLQ/B-155-20			Report Date	29/01/2020

SURGICAL PATHOLOGY REPORT

Rectal Polyp

DIAGNOSIS

INFLAMMATORY POLYP



SPECIMEN

Rectal Polyp

GROSS

Received 1x1 cm grayish white tissue piece.

Microscopy

Section examined shows mucosal lining epithelium with large number of submucosal glands with inflammatory cells (lymphocytes, polymorphs).

No granuloma seen. No malignant cells seen.

Note : All biopsy specimen will be stored for 15 (fifteen)days, block and slides for 5(five) years only from the time of receipt at the laboratory. No request ,for any of the above ,will be entertained after the due date.

Reference

- i) Rosai and Ackerman's Surgical Pathology.
- ii) Modern Surgical Pathology.

Gulshan Yadav, MD
Consultant Pathologist