

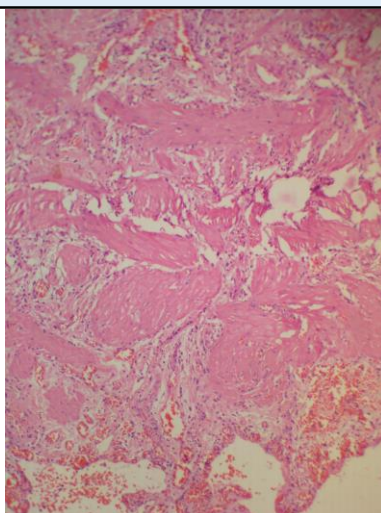
Patient Name	Mrs. KAVITA	Client Name	Family Hospital and Surgical Centre	Specimen Received	25/01/2020
Age/Sex	38YRS/F			Specimen Type	Tissue
Patient ID	012001250253			Collection Date	25/01/2020
Specimen ID	MOLQ/B-154-20			Report Date	29/01/2020

SURGICAL PATHOLOGY REPORT

Gall Bladder

DIAGNOSIS

CHOLECYSTITIS .



SPECIMEN

Gall Bladder

GROSS

Received 10x3.5cm long gall bladder. Cut section shows no stones. Wall Thickness 0.8 mm.

Microscopy

Section examined shows ulcerative mucosa and Rokitansky-Aschoff sinus (irregularly shaped tubular structures lined by cuboidal lining epithelium with round to oval nucleus) with fibro collagenous tissue and inflammatory cells (lymphocytes).

Note : All biopsy specimen will be stored for 15 (fifteen) days, block and slides for 5 (five) years only from the time of receipt at the laboratory. No request, for any of the above, will be entertained after the due date.

Reference

- i) Rosai and Ackerman's Surgical Pathology.
- ii) Modern Surgical Pathology.

Gulshan Yadav, MD
Consultant Pathologist