

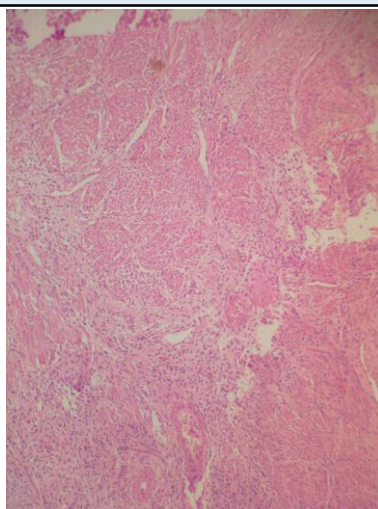
<b>Patient Name</b>	Mrs. GUDDI DEVI	<b>Client Name</b>	Uttam Diagnostics, Agra	<b>Specimen Received</b>	25/01/2020
<b>Age/Sex</b>	50YRS/F			<b>Specimen Type</b>	Tissue
<b>Patient ID</b>	012001250036			<b>Collection Date</b>	25/01/2020
<b>Specimen ID</b>	MOLQ/B-151/2020			<b>Report Date</b>	29/01/2020

## SURGICAL PATHOLOGY REPORT

### Uterus with Cervix

#### DIAGNOSIS

#### CHRONIC CERVICITIS



#### SPECIMEN

Uterus with Cervix

#### GROSS

Received 12x7 cm uterus with cervix with bilateral adnexa. Ovary size 3.5x3.5 cm, 3x2 cm (l ovary cut section shows straw coloured fluid and 2x2 cm uniloculated cvst).

#### Microscopy

Section examined shows

- 1) Endometrium with proliferative phase
- 2) Myometrium with muscle bundles
- 3) Cervix with mononuclear inflammatory cells
- 4) Simple cyst and tube unremarkable
- 5) Other ovary and tube unremarkable
- 6) Paratubal cyst with lining epithelium

**Note :** All biopsy specimen will be stored for 15 (fifteen) days, block and slides for 5 (five) years of reference at the laboratory. No request, for any of the above, will be entertained after the due date.

- References:
- i) Rosai and Ackerman's Surgical Pathology.
  - ii) Modern Surgical Pathology.

*Gulshan Yadav*  
of

**Gulshan Yadav, MD**  
Consultant Pathologist