

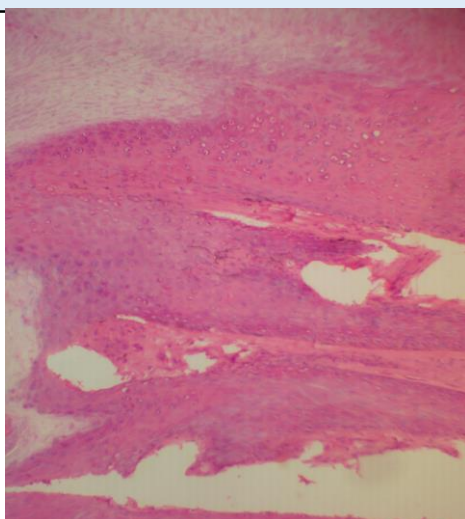
Patient Name	Mrs. PREETI	Client Name	Civil Hospital Sec-10	Specimen Received	24/01/2020
Age/Sex	18YRS/F			Specimen Type	Tissue
Patient ID	012001240275			Collection Date	24/01/2020
Specimen ID	MOLQ/B-149-2020			Report Date	29/01/2020

SURGICAL PATHOLOGY REPORT

Cutaneous Horn

DIAGNOSIS

BENIGN HYPERKERATOTIC LESION



SPECIMEN

Cutaneous Horn

GROSS

Received 2x3 cm grayish white tissue piece with skin attached.

Microscopy

Section examined shows squamous lining epithelium with round to oval nuclei with keratosis and hyperkeratosis. Deeper tissue shows fibrocollagenous tissue and blood vessels. No granuloma seen. No malignant cells seen.

Note : All biopsy specimen will be stored for 15 (fifteen) days, block and slides for 5 (five) years only from the time of receipt at the laboratory. No request, for any of the above, will be entertained after the due date.

Reference

- i) Rosai and Ackerman's Surgical Pathology.
- ii) Modern Surgical Pathology.

Gulshan Yadav, MD
Consultant Pathologist