

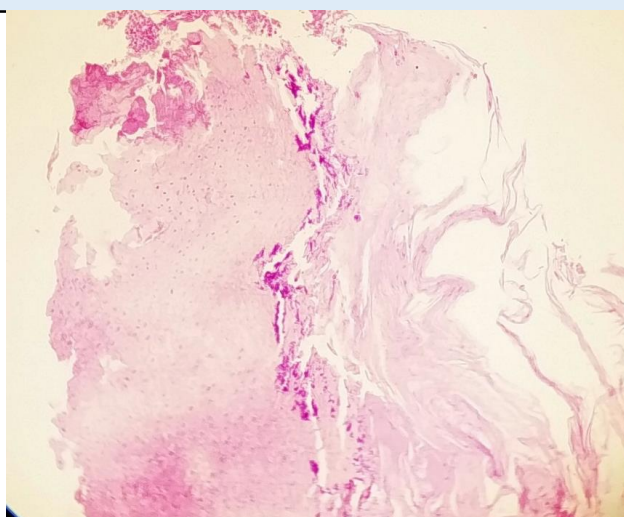
Patient Name	Mr. SHAMSHU	Client Name	Prakash Hospital	Specimen Received	22/01/2020
Age/Sex	17YRS/M			Specimen Type	Tissue
Patient ID	012001220228			Collection Date	22/01/2020
Specimen ID	MOLQ/B-138/2020			Report Date	27/01/2020

SURGICAL PATHOLOGY REPORT

Ruptured Subungual Glomus Tumor(Right little finger nail bed)

DIAGNOSIS

BENIGN MESENCHYMAL LESION.



SPECIMEN

Ruptured Subungual Glomus Tumor(Right little finger nail bed)

GROSS

Received tiny grayish white tissue piece.

Microscopy

Section examined shows squamous lining epithelium with keratosis and hyperkeratosis. Deeper tissue shows fibrocollagenous tissue with inflammatory cells.

No granuloma seen. No malignant cells seen.

Note : All biopsy specimen will be stored for 15 (fifteen)days, block and slides for 5(five) years only from the time of receipt at the laboratory. No request ,for any of the above ,will be entertained after the due date.

Reference

- i) Rosai and Ackerman's Surgical Pathology.
- ii) Modern Surgical Pathology.

Gulshan Yadav, MD
Consultant Pathologist