

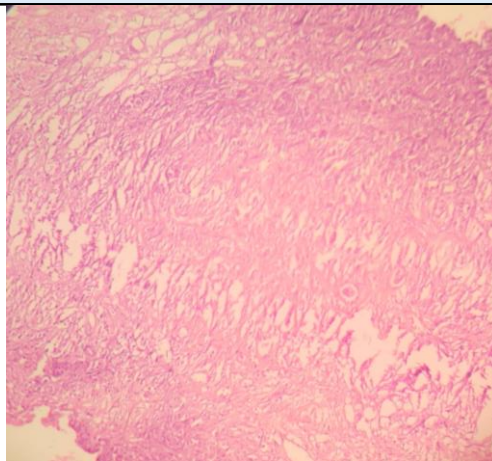
Patient Name	Mr. RANBIR 47053	Specimen Received	18-Jan-2020
Age/Sex	58 Years/Male	Specimen Type	Tissue
Patient ID	012001180202	Client Name	Pushpanjali Hospital
Specimen ID	MOLQ/B-108-2020	(Rewari)	
		Collection Date	18-Jan-2020
		Report Date	26-Jan-2020

SURGICAL PATHOLOGY REPORT

TURP Chips

DIAGNOSIS

Prostatic Adenocarcinoma, Gleason score 3+3=6



SPECIMEN

TURP Chips

GROSS

Received multiple grayish white tissue piece, 1x1 cm in aggregate.

Microscopy

1. Sections show prostate tru-cut biopsy pieces showing few prostatic glands in fibro-muscular stroma.
2. Glands are seen arranged back to back and are infiltrating the stroma.
3. These glands are lined by cuboidal epithelium showing mildly enlarged nuclei with hyperchromasia.

Note : All biopsy specimen will be stored for 15 (fifteen)days, block and slides for 5(five) years only from the time of receipt at the laboratory. No request ,for any of the above ,will be entertained after the due date.

Reference

- i) Rosai and Ackerman's Surgical Pathology.
- ii) Modern Surgical Pathology.

Gulshan Yadav, MD
Consultant Pathologist