

**Patient Name** Master. KUSHGAR  
**Age/Sex** 6YRS/M  
**Patient ID** 012001220197  
**Specimen ID** MOLQ/B-136/2020

**Client Name** Goyal Nursing Home, Palwal

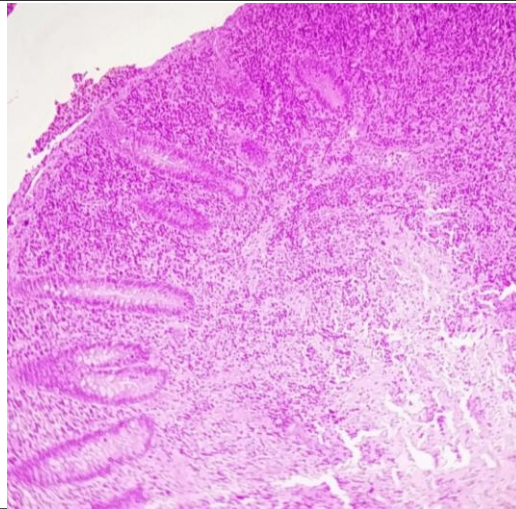
**Specimen Received** 22/01/2020  
**Specimen Type** Tissue  
**Collection Date** 22/01/2020  
**Report Date** 25/01/2020

## SURGICAL PATHOLOGY REPORT

### Appendix

#### DIAGNOSIS

#### ACUTE APPENDICITIS



#### SPECIMEN

Appendix

#### GROSS

Received 3.9x2.1cm long appendix. Cut section shows feco-lith.

#### Microscopy

Section examined shows lymphoid follicles with ulcerative mucosa. Deeper tissue shows inflammatory cells (polymorphs and lymphocytes). No granuloma seen. No malignant cells seen.

**Note :** All biopsy specimen will be stored for 15 (fifteen) days, block and slides for 5 (five) years only from the time of receipt at the laboratory. No request, for any of the above, will be entertained after the due date.

#### Reference

- i) Rosai and Ackerman's Surgical Pathology.
- ii) Modern Surgical Pathology.

A handwritten signature in black ink, appearing to read 'Gulshan', written over a light blue rectangular background.

**Gulshan Yadav, MD**  
Consultant Pathologist