

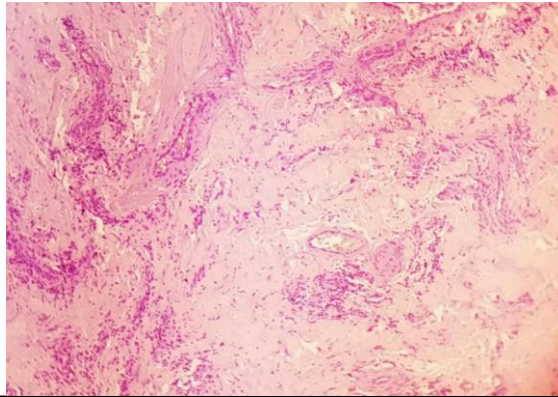
Patient Name	Mr. AVINASH KUMAR SHARMA	Client Name	Prakash Hospital	Specimen Received	21/01/2020
Age/Sex	31YRS/M			Specimen Type	Tissue
Patient ID	012001210184			Collection Date	21/01/2020
Specimen ID	MOLQ/B-130/2020			Report Date	25/01/2020

SURGICAL PATHOLOGY REPORT

Epididymal cyst

DIAGNOSIS

CHRONIC INFLAMMATORY LESION.



SPECIMEN

Epididymal cyst

GROSS

(Received 8.5X3cm grayish white tissue piece.)


Microscopy

Section examined shows fibrocollagenous tissue with large number of blood vessels with surrounding by mononuclear inflammatory cells, occasional histiocytes. No granuloma seen. No malignant cells seen.

Note : All biopsy specimen will be stored for 15 (fifteen)days, block and slides for 5(five) years only from the time of receipt at the laboratory. No request ,for any of the above ,will be entertained after the due date.

Reference

- i) Rosai and Ackerman's Surgical Pathology.
- ii) Modern Surgical Pathology.


Gulshan Yadav, MD
Consultant Pathologist