

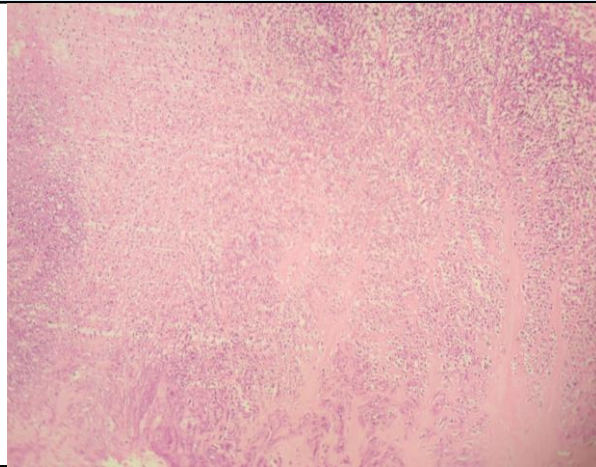
<b>Patient Name</b>	<b>Mr. PRAKASH SINGH</b>	<b>Specimen Received</b>	19-Jan-2020
<b>Age/Sex</b>	46 Years/Male	<b>Specimen Type</b>	Tissue
<b>Patient ID</b>	012001190192	<b>Client Name</b>	Shiva Hospital
<b>Specimen ID</b>	MOLQ/B-121-2020	<b>Collection Date</b>	19-Jan-2020
		<b>Report Date</b>	24-Jan-2020

## SURGICAL PATHOLOGY REPORT

Vertebral Tissue (C4, C5 Region).

### DIAGNOSIS

**ACUTE ON CHRONIC INFECTIVE LESION.**



#### SPECIMEN

Vertebral Tissue (C4, C5 Region).

#### GROSS

Received autolyzed multiple grayish white tissue piece.

#### Microscopy

- Section examined shows lymphocytes, polymorphs, occasionally histiocytes with presence of granular necrosis.
- Presence of cartilage and spicules.  
No granuloma seen. No malignant cells seen.

**Note :** All biopsy specimen will be stored for 15 (fifteen) days, block and slides for 5 (five) years only from the time of receipt at the laboratory. No request, for any of the above, will be entertained after the due date.

#### Reference

- Rosai and Ackerman's Surgical Pathology.
- Modern Surgical Pathology.

**Gulshan Yadav, MD**  
Consultant Pathologist