

Patient Name Mr. JILSHAD
Age/Sex 19YRS/M
Patient ID 012001200291
Specimen ID MOLQ/B-124/2020

Client Name Dinesh Lab, Bhiwari

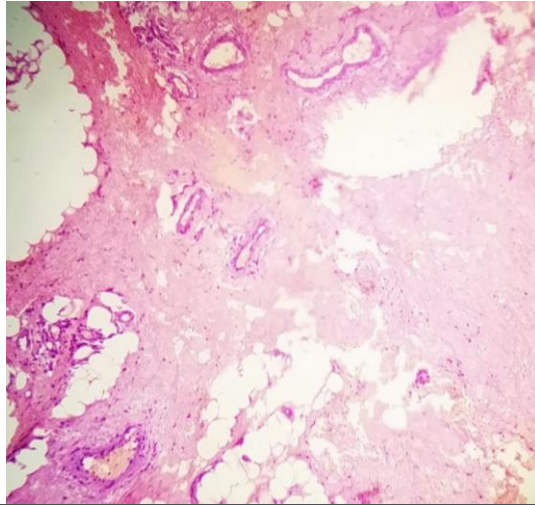
Specimen Received 20/01/2020
Specimen Type Tissue
Collection Date 20/01/2020
Report Date 23/01/2020

SURGICAL PATHOLOGY REPORT

Lipoma

DIAGNOSIS

BENIGN MESENCHYMAL LESION



SPECIMEN

Lipoma

GROSS

Received 4.1X2.9CM grayish white tissue piece.

Microscopy


Section examined shows fibrocollagenous tissue and mature adipose cells with inflammatory cell and blood vessels.

No granuloma seen. No malignant cells seen.

Note : All biopsy specimen will be stored for 15 (fifteen)days, block and slides for 5(five) years only from the time of receipt at the laboratory. No request ,for any of the above ,will be entertained after the due date.

Reference

- i) Rosai and Ackerman's Surgical Pathology.
- ii) Modern Surgical Pathology.



Gulshan Yadav, MD
Consultant Pathologist