

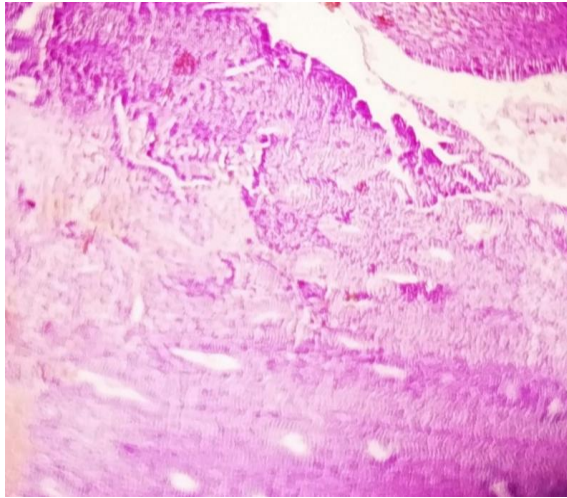
Patient Name	Mrs. ANSHU W/O PARDEEP	Client Name	Lalita Memorial Hospital Pvt. Ltd. (Rewari)	Specimen Received	20/01/2020
Age/Sex	35YRS/F			Specimen Type	Tissue
Patient ID	012001200266			Collection Date	20/01/2020
Specimen ID	MOLQ/B-123/2020			Report Date	23/01/2020

SURGICAL PATHOLOGY REPORT

Endometrium

DIAGNOSIS

DISORDERED PROLIFERATIVE PHASE



SPECIMEN

Endometrium

GROSS

Received autolyzed multiple grayish white tissue piece.

Microscopy

Section examined shows small and tortuous endometrial glands with columnar lining with small round to oval nucleus. Stroma shows mononuclear inflammatory cells and RBCs. No granuloma seen. No malignant cells seen.

Note : All biopsy specimen will be stored for 15 (fifteen) days, block and slides for 5 (five) years only from the time of receipt at the laboratory. No request, for any of the above, will be entertained after the due date.

Reference

- i) Rosai and Ackerman's Surgical Pathology.
- ii) Modern Surgical Pathology.

Gulshan Yadav, MD
Consultant Pathologist