

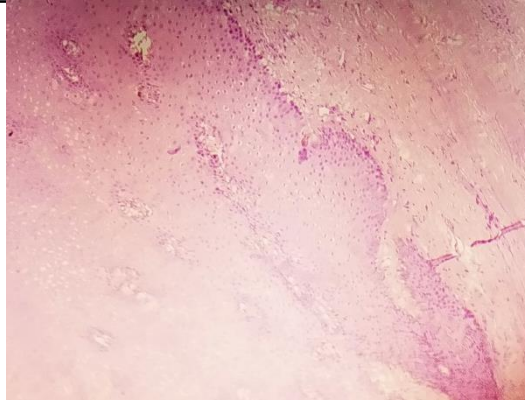
Patient Name	Mr. MANOJ KUMAR	Client Name	Kriti Hospital	Specimen Received	19/01/2020
Age/Sex	30YRS/M			Specimen Type	Tissue
Patient ID	012001190057			Collection Date	19/01/2020
Specimen ID	MOLQ/B-117/2020			Report Date	23/01/2020

SURGICAL PATHOLOGY REPORT

Perianal Fibrotic Swelling

DIAGNOSIS

BENIGN MESENCHYMAL LESION.



SPECIMEN

Perianal Fibrotic Swelling

GROSS

Received 1.9x0.9cm grayish white tissue piece.

Microscopy

Section examined shows squamous lining epithelial cells with round nucleus with mild parakeratosis.

Deeper tissue shows fibrocollagenous tissue with blood vessels, muscle bundle with inflammatory cells. No granuloma seen. No malignant cells seen.

Note : All biopsy specimen will be stored for 15 (fifteen) days, block and slides for 5 (five) years only from the time of receipt at the laboratory. No request, for any of the above, will be entertained after the due date.

Reference

- i) Rosai and Ackerman's Surgical Pathology.
- ii) Modern Surgical Pathology.

Gulshan Yadav, MD
Consultant Pathologist