

Patient Name Mrs. BIRWATI
Age/Sex 35YRS/F
Patient ID 012001180248
Specimen ID MOLQ/B-114/2020

Client Name Civil Hospital Sec-10

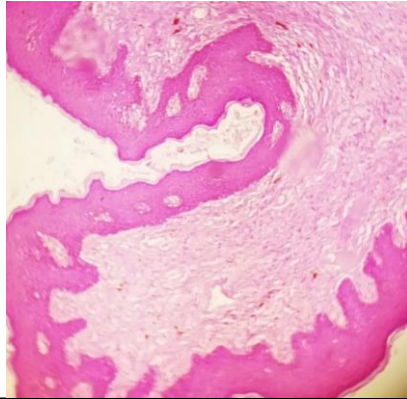
Specimen Received 18/01/2020
Specimen Type Tissue
Collection Date 18/01/2020
Report Date 22/01/2020

SURGICAL PATHOLOGY REPORT

Left Labia Minora Cyst

DIAGNOSIS

INFECTED CYSTIC LESION.



SPECIMEN

Left Labia Minora Cyst

GROSS

Received 3.7x2.9cm long cystic tissue piece with skin attached.


Microscopy

Section examined shows squamous lining epithelial cells with parakeratosis and Hyperkeratosis. Deeper tissue shows melanin pigmentation having large number of inflammatory cell(Lymphocytes , Plasma cells)with blood vessels.

Note : All biopsy specimen will be stored for 15 (fifteen)days, block and slides for 5(five) years only from the time of receipt at the laboratory. No request ,for any of the above ,will be entertained after the due date.

Reference

- i) Rosai and Ackerman's Surgical Pathology.
- ii) Modern Surgical Pathology.


Gulshan Yadav, MD
Consultant Pathologist