

Patient Name Mrs. RADHA
Age/Sex 24YRS/F
Patient ID 012001180036
Specimen ID MOLQ/B-104/2020

Client Name Chirag Diagnostics

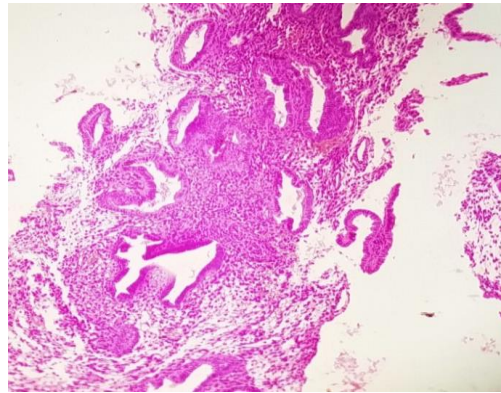
Specimen Received 18/01/2020
Specimen Type Tissue
Collection Date 18/01/2020
Report Date 22/01/2020

SURGICAL PATHOLOGY REPORT

Endometrium

DIAGNOSIS

PROLIFERATIVE PHASE WITH BLEEDING ENDOMETRIUM



SPECIMEN

Endometrium

GROSS

Received multiple grayish white tissue piece.


Microscopy

Section examined shows scanty cellularity with few small endometrial glands with cuboidal to columnar lining with small round nucleus having large numbers of RBCs with Stromal cells. No granuloma seen. No malignant cells seen.

Note : All biopsy specimen will be stored for 15 (fifteen)days, block and slides for 5(five) years only from the time of receipt at the laboratory. No request ,for any of the above ,will be entertained after the due date.

Reference

- i) Rosai and Ackerman's Surgical Pathology.
- ii) Modern Surgical Pathology.


Gulshan Yadav, MD
Consultant Pathologist