

**Patient Name** Mrs. SUNITA  
**Age/Sex** 27YRS/F  
**Patient ID** 012001160128  
**Specimen ID** MOLQ/B-97/2020

**Client Name** Gobind Hospital

**Specimen Received** 18/01/2020  
**Specimen Type** Tissue  
**Collection Date** 18/01/2020  
**Report Date** 22/01/2020

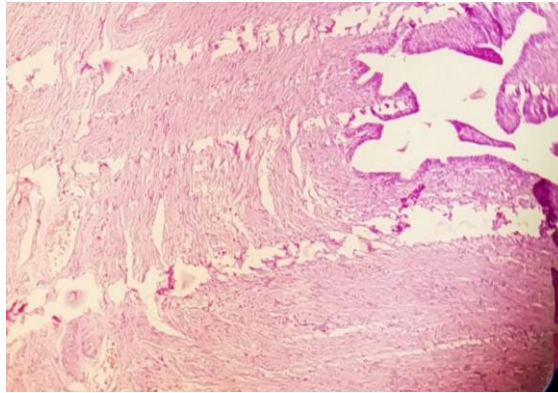
## SURGICAL PATHOLOGY REPORT

(II) Container: Right Tube( ectopic pregnancy)

(III) Container: Left Tube

### DIAGNOSIS

**KINDLY CO- RELATE WITH CLINICAL AND RADIOLOGICAL AND BETA HCG FINDINGS.**



### **SPECIMEN**

(II) Container: Right Tube( ectopic pregnancy)  
(III) Container: Left Tube

### **GROSS**

(II) Container: Received 0.5x0.5cm tubular tissue piece.  
(III) Container: Received 0.5x0.5cm tubular tissue piece.


### **Microscopy**

(II) Section examined shows tubal lining epithelial cells with round to oval nucleus. No trophoblastic cells seen in the lumen. No decidual cells seen.  
(III) Left tube confirmed and unremarkable.

**Note :** All biopsy specimen will be stored for 15 (fifteen) days, block and slides for 5 (five) years only from the time of receipt at the laboratory. No request ,for any of the above ,will be entertained after the due date.

### **Reference**

- i) Rosai and Ackerman's Surgical Pathology.
- ii) Modern Surgical Pathology.

  
**Gulshan Yadav, MD**  
Consultant Pathologist