

Patient Name. Mr. DEVENDER
Age/Sex 42 YRS/M
Patient ID 012001170203
Specimen ID MOLQ/B-103/2020

Client Name Goyal Nursing Home, Palwal

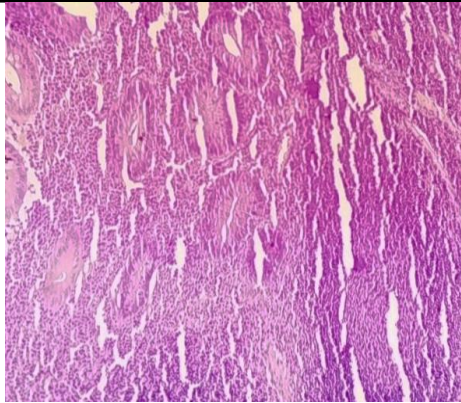
Specimen Received 17/01/2020
Specimen Type Tissue
Collection Date 17/01/2020
Report Date 20/01/2020

SURGICAL PATHOLOGY REPORT

Appendix

DIAGNOSIS

ACUTE APPENDICITIS



SPECIMEN

Appendix

GROSS

Received 6.2x1.8cm long appendix. Cut section shows feco-lith.


Microscopy

Section examined shows lymphoid follicles with ulcerative mucosa. Deeper tissue shows inflammatory cells (polymorphs and lymphocytes). No granuloma seen. No malignant cells seen.

Note : All biopsy specimen will be stored for 15 (fifteen)days, block and slides for 5(five) years only from the time of receipt at the laboratory. No request ,for any of the above ,will be entertained after the due date.

Reference

- i) Rosai and Ackerman's Surgical Pathology.
- ii) Modern Surgical Pathology.


Gulshan Yadav, MD
Consultant Pathologist