

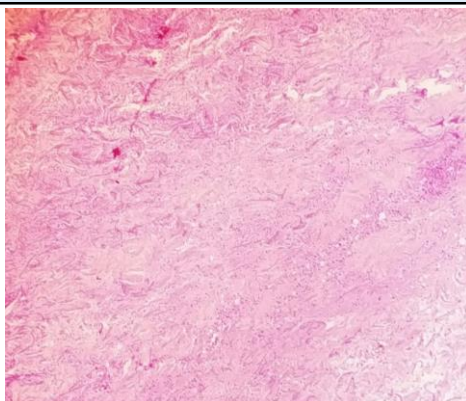
Patient Name	Mr. HAKMUDIN	Client Name	Dinesh Lab, Bhiwari	Specimen Received	15/01/2020
Age/Sex	55YRS/M			Specimen Type	Tissue
Patient ID	012001150163			Collection Date	15/01/2020
Specimen ID	MOLQ/B-88/2020			Report Date	18/01/2020

SURGICAL PATHOLOGY REPORT

Swelling Left leg

DIAGNOSIS

INFECTIVE LESION.



SPECIMEN

Swelling Left leg

GROSS

Received multiple grayish white tissue piece, 2x3 cm in aggregate.

Microscopy

Section examined shows fibrocollagenous, mature adipose cells with large number of inflammatory cells (Polymorphs, Lymphocytes) with necrosis.

No granuloma seen. No malignant cells seen.

Note : All biopsy specimen will be stored for 15 (fifteen)days, block and slides for 5(five) years only from the time of receipt at the laboratory. No request ,for any of the above ,will be entertained after the due date.

Reference

- i) Rosai and Ackerman's Surgical Pathology.
- ii) Modern Surgical Pathology.

Gulshan Yadav, MD
Consultant Pathologist