

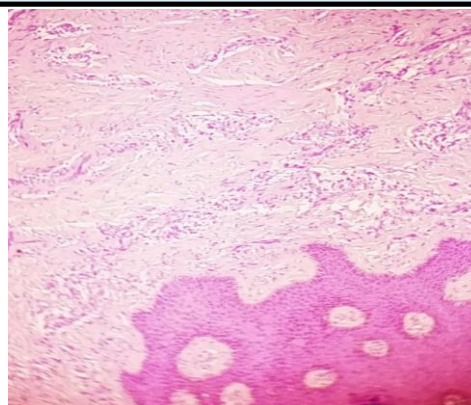
<b>Patient Name</b>	Mr. ASHOK RAJAK	<b>Client Name</b>	Lifeaid Wellness Centre	<b>Specimen Received</b>	13/01/2020
<b>Age/Sex</b>	26YRS/M			<b>Specimen Type</b>	Tissue
<b>Patient ID</b>	012001130256			<b>Collection Date</b>	13/01/2020
<b>Specimen ID</b>	MOLQ/B-74/2020			<b>Report Date</b>	16/01/2020

## SURGICAL PATHOLOGY REPORT

### Pilonidal sinus

#### DIAGNOSIS

**NON SPECIFIC INFLAMMATION.**



#### **SPECIMEN**

Pilonidal sinus

#### **GROSS**

Received 2.9x3.6cm grayish white tissue piece with skin attached.

#### **Microscopy**

Section examined shows squamous lining epithelial with round to oval nucleus with fibrocollagenous. mature adipose cells with blood vessels and inflammatory cells (Lymphocytes, plasma cells)

No granuloma seen. No malignant cells seen.

**Note :** All biopsy specimen will be stored for 15 (fifteen)days, block and slides for 5(five) years only from the time of receipt at the laboratory. No request ,for any of the above ,will be entertained after the due date.

#### **Reference**

- i) Rosai and Ackerman's Surgical Pathology.
- ii) Modern Surgical Pathology.

**Gulshan Yadav, MD**  
Consultant Pathologist