

Patient Name Mr. KULTAR CHAND
Age/Sex 43YRS/M
Patient ID 012001100166
Specimen ID MOLQ/B-61/2020

Client Name Polaris Hospital

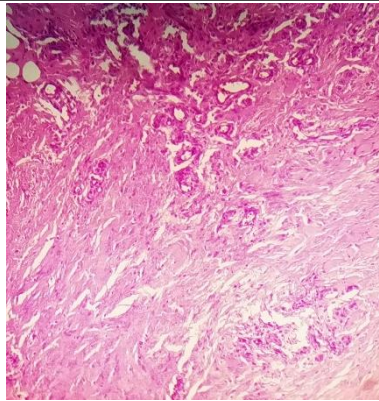
Specimen Received 10/01/2020
Specimen Type Tissue
Collection Date 10/01/2020
Report Date 16/01/2020

SURGICAL PATHOLOGY REPORT

Swelling Right Ankle

DIAGNOSIS

KERATIGENOUS CYST.



SPECIMEN

Swelling Right Ankle

GROSS

Received 3x2cm grayish white tissue piece. Cut section shows cheesy and necrotic material.

Microscopy

Section examined shows squamous lining epithelial cells with round to oval nucleus along with hyperkeratosis and parakeratosis. Deeper tissue shows fibrocollagenous tissue, blood vessels, mature adipose cells and inflammatory cells (Lymphocytes, plasma cells) with glands. No granuloma seen. No malignant cells seen.

Note : All biopsy specimen will be stored for 15 (fifteen) days, block and slides for 5 (five) years only from the time of receipt at the laboratory. No request, for any of the above, will be entertained after the due date.

Reference

- i) Rosai and Ackerman's Surgical Pathology.
- ii) Modern Surgical Pathology.

Gulshan Yadav, MD
Consultant Pathologist