

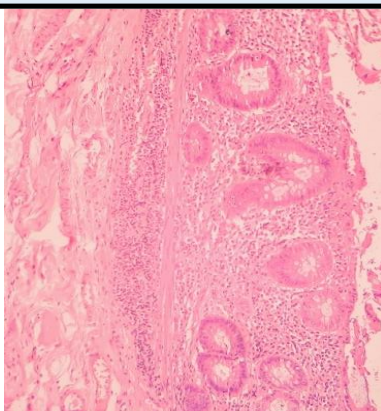
Patient Name	Mrs. BURO DEVI	Client Name	S. M. Diagnostics, Kaithal	Specimen Received	08/01/2020
Age/Sex	65YRS/F			Specimen Type	Tissue
Patient ID	012001080086			Collection Date	08/01/2020
Specimen ID	MOLQ/B-35-20			Report Date	16/01/2020

SURGICAL PATHOLOGY REPORT

Appendix

DIAGNOSIS

ACUTE APPENDICITIS



SPECIMEN

Appendix

GROSS

Received 4.9x1.3 cm long appendix with mesoappendix. Cut section shows feco-lith.

Microscopy

Section examined shows lymphoid follicles with ulcerative mucosa. Deeper tissue shows inflammatory cells (polymorphs and lymphocytes). No granuloma seen. No malignant cells seen.

Note : All biopsy specimen will be stored for 15 (fifteen)days, block and slides for 5(five) years only from the time of receipt at the laboratory. No request ,for any of the above ,will be entertained after the due date.

Reference

- i) Rosai and Ackerman's Surgical Pathology.
- ii) Modern Surgical Pathology.

Gulshan Yadav, MD
Consultant Pathologist