

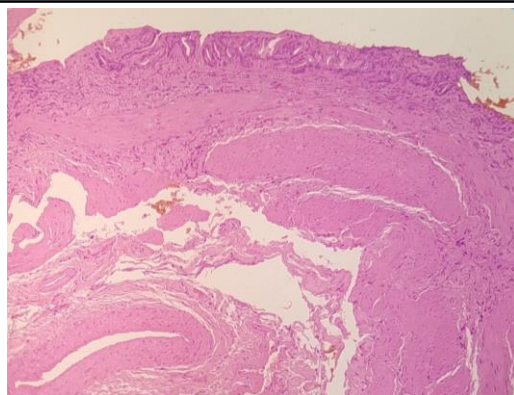
Patient Name	Mrs. KUSUM GAUTAM	Client Name	Goyal Nursing Home, Palwal	Specimen Received	10/01/2020
Age/Sex	48YRS/F			Specimen Type	Tissue
Patient ID	012001100219			Collection Date	10/01/2020
Specimen ID	MOLQ/B-62/2020			Report Date	14/01/2020

SURGICAL PATHOLOGY REPORT

Gall Bladder

DIAGNOSIS

CHOLECYSTITIS AND CHOLELITHIASIS.



SPECIMEN

Gall Bladder

GROSS

Received 5x2.1cm long gall bladder. Cut section shows tiny stones.

Microscopy

Section examined shows ulcerative mucosa and Rokitansky-Aschoff sinuses (irregularly shaped tubular structures lined by cuboidal lining epithelium with round to oval nucleus) with fibro collagenous tissue and inflammatory cells (lymphocytes).

Note : All biopsy specimen will be stored for 15 (fifteen) days, block and slides for 5 (five) years only from the time of receipt at the laboratory. No request, for any of the above, will be entertained after the due date.

Reference

- i) Rosai and Ackerman's Surgical Pathology.
- ii) Modern Surgical Pathology.

Gulshan Yadav, MD
Consultant Pathologist