

Patient Name Mrs. SINDHO DEVI
Age/Sex 40YRS/F
Patient ID 012001090018
Specimen ID MOLQ/B-38/2020

Client Name S. M. Diagnostics, Kaithal

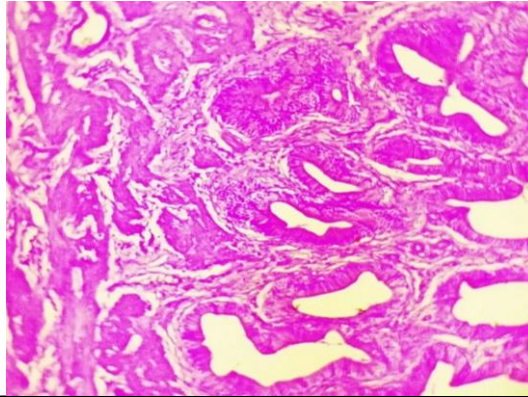
Specimen Received 09/01/2020
Specimen Type Tissue
Collection Date 09/01/2020
Report Date 12/01/2020

SURGICAL PATHOLOGY REPORT

Gall Bladder

DIAGNOSIS

CHOLECYSTITIS AND CHOLELITHIASIS.



SPECIMEN

Gall Bladder

GROSS

Received 7.5x1.9cm long gall bladder. already cut open with stones. Wall thickness 0.6mm.


Microscopy

Section examined shows ulcerative mucosa and Rokitansky-Aschoff sinuses (irregularly shaped tubular structures lined by cuboidal lining epithelium with round to oval nucleus) with fibrocollagenous tissue and inflammatory cells (lymphocytes).

Note : All biopsy specimen will be stored for 15 (fifteen) days, block and slides for 5 (five) years only from the time of receipt at the laboratory. No request, for any of the above, will be entertained after the due date.

Reference

- i) Rosai and Ackerman's Surgical Pathology.
- ii) Modern Surgical Pathology.


Gulshan Yadav, MD
Consultant Pathologist