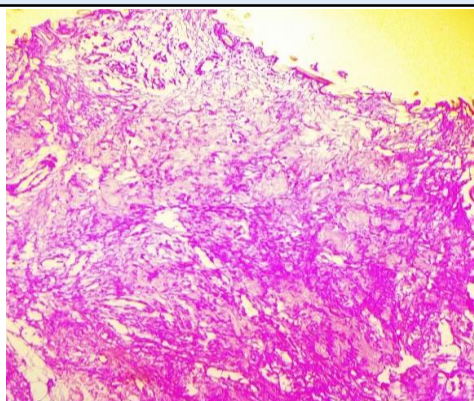


Patient Name	Ms. CHANDA	Client Name	Civil Hospital Sec-10	Specimen Received	08/01/2020
Age/Sex	28YRS/F			Specimen Type	Tissue
Patient ID	012001080223			Collection Date	08/01/2020
Specimen ID	MOLQ/B-49-20			Report Date	12/01/2020

SURGICAL PATHOLOGY REPORT
Myocysticercosis (Forearm)

DIAGNOSIS

PARASITIC INFESTATION (STRONGLY SUSPICIOUS OF CYSTICERCOSIS)



SPECIMEN

Myocysticercosis (Forearm)

GROSS

Received two tiny greyish white tissue piece.

Microscopy

Section examined shows squamous lining epithelium with small round nucleus. Deeper tissue shows fibrocollagenous tissue, blood vessels with inflammatory cells (Polymorphs, Lymphocytes and Plasma cells). Section also shows membranous tissue.

No well-formed granuloma seen. No malignant cells seen.

Note : All biopsy specimen will be stored for 15 (fifteen)days, block and slides for 5(five) years only from the time of receipt at the laboratory. No request ,for any of the above ,will be entertained after the due date.

Reference

- i) Rosai and Ackerman's Surgical Pathology.
- ii) Modern Surgical Pathology.

Gulshan Yadav, MD
Consultant Pathologist