

Patient Name Mrs. BABITA
Age/Sex 43YRS/F
Patient ID 012001080179
Specimen ID MOLQ/B-47/2020

Client Name Lalita Memorial Hospital Pvt.
Ltd. (Rewari)

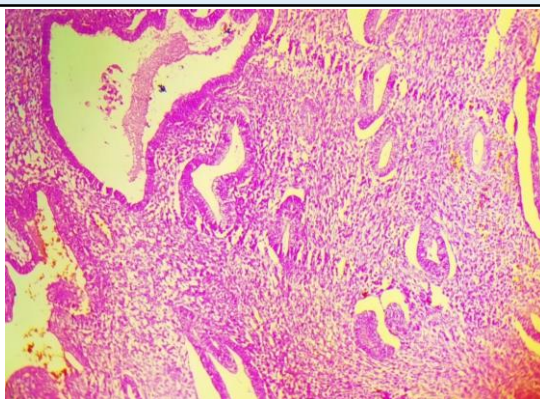
Specimen Received 08/01/2020
Specimen Type Tissue
Collection Date 08/01/2020
Report Date 12/01/2020

SURGICAL PATHOLOGY REPORT

Uterus with Cervix

DIAGNOSIS

CHRONIC CERVICITIS



SPECIMEN

Uterus with Cervix

GROSS

Received 7x5 cm uterus with cervix with unilateral tube. Cut section shows Nabothian cyst.

Microscopy

Section examined shows

- 1) Endometrium with proliferative phase
- 2) Myometrium with adenomyosis
- 3) Cervix with mononuclear inflammatory cells with Nabothian cyst
- 4) Tube unremarkable

Note : All biopsy specimen will be stored for 15 (fifteen) days, block and slides for 5 (five) years only from the time of receipt at the laboratory. No request, for any of the above, will be entertained after the due date.

Reference

- i) Rosai and Ackerman's Surgical Pathology.
- ii) Modern Surgical Pathology.

Gulshan Yadav, MD
Consultant Pathologist