

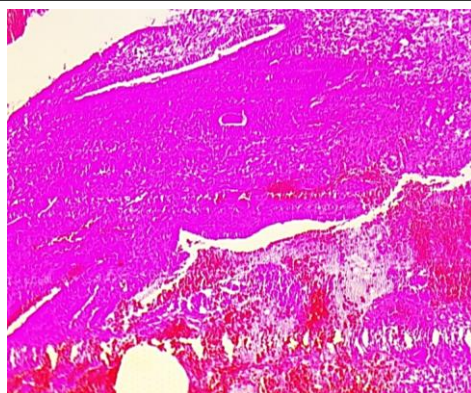
<b>Patient Name</b>	Mrs. SANTOSH	<b>Client Name</b>	Aggarwal Path Lab, NUH	<b>Specimen Received</b>	07/01/2020
<b>Age/Sex</b>	38YRS/F			<b>Specimen Type</b>	Tissue
<b>Patient ID</b>	012001070234			<b>Collection Date</b>	07/01/2020
<b>Specimen ID</b>	MOLQ/B-31/2020			<b>Report Date</b>	13/01/2020

## SURGICAL PATHOLOGY REPORT

### Endometrium

#### DIAGNOSIS

#### DISORDERED PROLIFERATIVE PHASE



#### SPECIMEN

Endometrium

#### GROSS

Received multiple grayish white tissue piece.

#### Microscopy

Section examined shows small and tortuous endometrial glands with cuboidal lining with small round nucleus. Stroma shows mononuclear inflammatory cells.

No granuloma seen. No malignant cells seen.

**Note :** All biopsy specimen will be stored for 15 (fifteen) days, block and slides for 5 (five) years only from the time of receipt at the laboratory. No request, for any of the above, will be entertained after the due date.

#### Reference

- i) Rosai and Ackerman's Surgical Pathology.
- ii) Modern Surgical Pathology.

**Gulshan Yadav, MD**  
Consultant Pathologist