

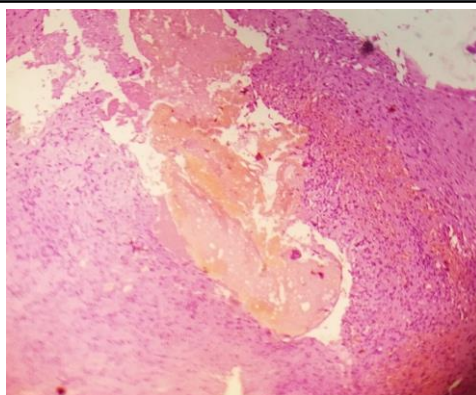
Patient Name	Mrs. BABLI	Client Name	Chetanya Hospital	Specimen Received	02/01/2020
Age/Sex	22YRS/F			Specimen Type	Tissue
Patient ID	012001020111			Collection Date	02/01/2020
Specimen ID	MOLQ/B-7/2020			Report Date	09/01/2020

SURGICAL PATHOLOGY REPORT

Left Ovarian Cyst

DIAGNOSIS

HEMORRHAGIC CYST.



SPECIMEN

Left Ovarian Cyst

GROSS

Received multiple grayish white tissue piece, 1.5x1.2 cm in aggregate.

Microscopy


Section examined shows ovarian tissue having small round to oval nucleus with inflammatory cells and large numbers of RBCs.

No granuloma seen. No malignant cells seen.

Note : All biopsy specimen will be stored for 15 (fifteen) days, block and slides for 5 (five) years only from the time of receipt at the laboratory. No request, for any of the above, will be entertained after the due date.

Reference

- i) Rosai and Ackerman's Surgical Pathology.
- ii) Modern Surgical Pathology.


Gulshan Yadav, MD
Consultant Pathologist