

Patient Name Ms. SAROJANI
Age/Sex 40YRS/F
Patient ID 012001030226
Specimen ID MOLQ/B-10/20

Client Name Kriti Hospital

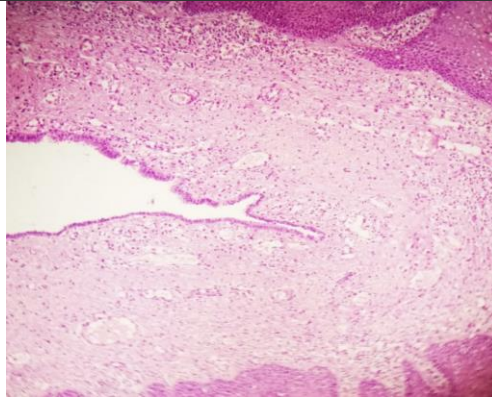
Specimen Received 03/01/2020
Specimen Type Tissue
Collection Date 03/01/2020
Report Date 07/01/2020

SURGICAL PATHOLOGY REPORT

Vaginal Cyst Wall

DIAGNOSIS

BENIGN CYSTIC LESION



SPECIMEN

Vaginal Cyst Wall

GROSS

Received 3.2x2.1cm grayish white tissue piece.


Microscopy

Section examined shows squamous lining epithelial cells with round to oval nucleus. Cyst lumen lined shows cuboidal lining epithelium with stromal cells and mononuclear inflammatory cells. No granuloma seen. No malignant cells seen.

Note : All biopsy specimen will be stored for 15 (fifteen)days, block and slides for 5(five) years only from the time of receipt at the laboratory. No request ,for any of the above ,will be entertained after the due date.

Reference

- i) Rosai and Ackerman's Surgical Pathology.
- ii) Modern Surgical Pathology.


Gulshan Yadav, MD
Consultant Pathologist