

Patient Name	Mr. SAHAB RAM	Client Name	Galaxy Hospital, Palwal	Specimen Received	02/01/2020
Age/Sex	65 Years/Male			Specimen Type	Tissue
Patient ID	012001020137			Collection Date	02/01/2020
Specimen ID	MOLQ/B-08-20			Report Date	07/01/2020

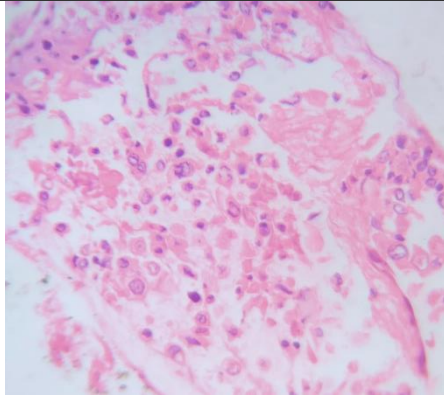
SURGICAL PATHOLOGY REPORT

Left Lung Bronchus Mass Lesion (Bronchoscopy)

DIAGNOSIS

ATYPICAL EPITHELIAL CELL LESION (SUSPICIOUS OF NON-SMALL CELL LUNG CARCINOMA)

Advised: Immunohistochemical studies with ALK, Ros-1 and PD-L1.



SPECIMEN

Left Lung Bronchus Mass Lesion
(Bronchoscopy)

GROSS

Received tiny grayish white tissue piece.

Microscopy

1. Paucicellular section examined shows epithelial cells with large number of atypical nucleus with irregular margins with necrosis, fibrocollagenous tissue and inflammatory cells.
2. No granuloma seen.

Note : All biopsy specimen will be stored for 15 (fifteen) days, block and slides for 5 (five) years only from the time of receipt at the laboratory. No request ,for any of the above ,will be entertained after the due date.

Reference

- i) Rosai and Ackerman's Surgical Pathology.
- ii) Modern Surgical Pathology.

Gulshan Yadav, MD
Consultant Pathologist