

Patient Name	Baby. KHUSH PREET	Client Name	Nath Nursing Home, Jind	Specimen Received	02/01/2020
Age/Sex	2YRS/F			Specimen Type	Tissue
Patient ID	012001020014			Collection Date	02/01/2020
Specimen ID	MOLQ/B-01/20			Report Date	06/01/2020

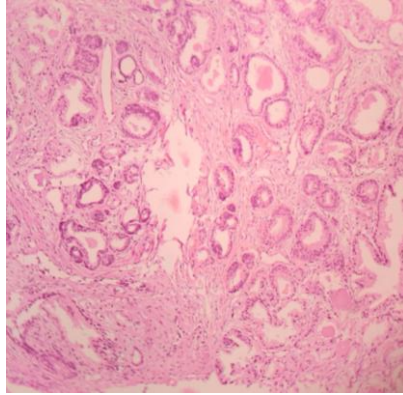
SURGICAL PATHOLOGY REPORT

Rectal Polyp

DIAGNOSIS

INFLAMMATORY POLYP WITH REACTIVE ATYPIA

ADVISED: Kindly, co-relate with radiological findings



SPECIMEN

Rectal Polyp

GROSS

Received 1x1 cm greyish white tissue piece.

Microscopy

Section examined shows mucosal lining epithelium with sub mucosal lining cells having columnar cells having round to oval nucleus with mild anisonucleosis with large number of inflammatory cells (polymorphs, lymphocytes and plasma cells).

Note : All biopsy specimen will be stored for 15 (fifteen)days, block and slides for 5(five) years only from the time of receipt at the laboratory. No request ,for any of the above ,will be entertained after the due date.

Reference

- i) Rosai and Ackerman's Surgical Pathology.
- ii) Modern Surgical Pathology.

Gulshan Yadav, MD
Consultant Pathologist