

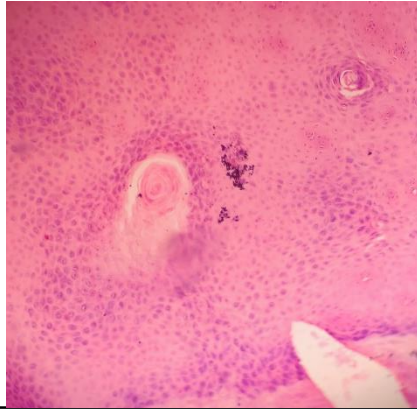
Patient Name	Mr. ZAKIR KHAN/KHURHAMA	Specimen Received	31/12/19
Age/Sex	19YRS/M	Specimen Type	Tissue
Patient ID	011912310227	Collection Date	31/12/19
Specimen ID	MOLQ/B-2476/19	Report Date	06/01/20

SURGICAL PATHOLOGY REPORT

Non-healing Ulcer 2nd Web Space (Right Foot)

DIAGNOSIS

HYPERKERATOTIC LESION WITH PYOGENIC GRANULOMA



SPECIMEN

Non-healing Ulcer 2nd Web Space (Right Foot)

GROSS

Received multiple grayish white tissue piece.

Microscopy

1. Section examined shows squamous lining epithelium with hyperkeratosis and parakeratosis with mild anisonucleosis.
2. Presence of keratin pearls in the superficial part of epithelium.
3. Deeper tissue shows fibrocollagenous tissue with large number of blood vessels.

Note : All biopsy specimen will be stored for 15 (fifteen)days, block and slides for 5(five) years only from the time of receipt at the laboratory. No request ,for any of the above ,will be entertained after the due date.

Reference

- i) Rosai and Ackerman's Surgical Pathology.
- ii) Modern Surgical Pathology.

Gulshan Yadav, MD
Consultant Pathologist