

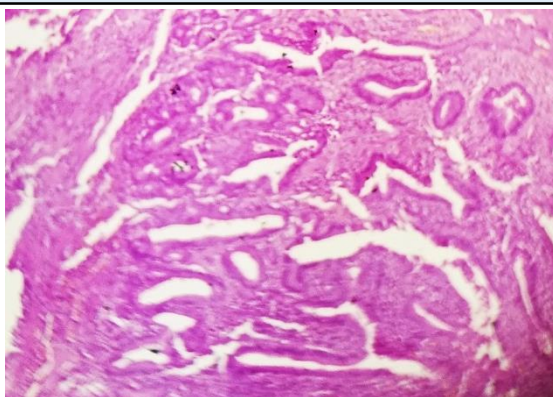
Patient Name	Mrs. POOJA	Client Name	Shri Balaji Multispeciality Hospital-Gurgaon	Specimen Received	31/12/19
Age/Sex	28YRS/F			Specimen Type	Tissue
Patient ID	011912310140			Collection Date	31/12/19
Specimen ID	MOLQ/B-2473/19			Report Date	02/01/2020

SURGICAL PATHOLOGY REPORT

Gall Bladder

DIAGNOSIS

CHOLECYSTITIS AND CHOLELITHIASIS.



SPECIMEN

Gall Bladder

GROSS

Received 6.8x2.9cm long gall bladder. Cut section shows stones. Wall thickness 0.6 mm.

Microscopy

Section examined shows ulcerative mucosa and Rokitansky-Aschoff sinus (irregularly shaped tubular structures lined by cuboidal lining epithelium with round to oval nucleus) with fibro collagenous tissue and inflammatory cells (lymphocytes).

Note : All biopsy specimen will be stored for 15 (fifteen) days, block and slides for 5 (five) years only from the time of receipt at the laboratory. No request, for any of the above, will be entertained after the due date.

Reference

- i) Rosai and Ackerman's Surgical Pathology.
- ii) Modern Surgical Pathology.

Gulshan Yadav, MD
Consultant Pathologist