

Patient Name Mr. NAVJEET
Age/Sex 35YRS/M
Patient ID 011912300103
Specimen ID MOLQ/B-2468/19

Client Name Polaris Hospital

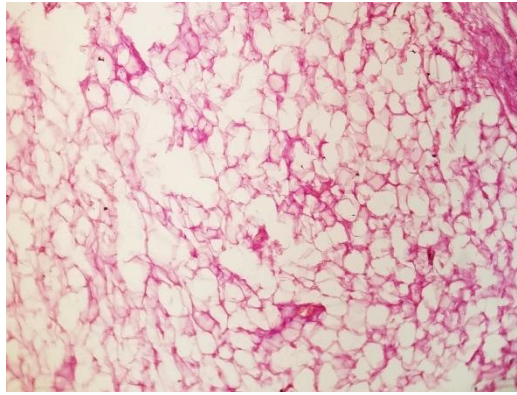
Specimen Received 30/12/19
Specimen Type Tissue
Collection Date 30/12/19
Report Date 02/01/2020

SURGICAL PATHOLOGY REPORT

Lipoma (Left side of fore head)

DIAGNOSIS

BENIGN MESENCHYMAL LESION



SPECIMEN

Lipoma (Left side of fore head)

GROSS

Received 1x1.5 cm greyish white tissue piece.

Microscopy


Section examined shows mature adipose cells, fibrocollagenous tissue with blood vessels and muscle bundle.

No granuloma seen. No malignant cells seen.

Note : All biopsy specimen will be stored for 15 (fifteen) days, block and slides for 5 (five) years only from the time of receipt at the laboratory. No request, for any of the above, will be entertained after the due date.

Reference

- i) Rosai and Ackerman's Surgical Pathology.
- ii) Modern Surgical Pathology.


Gulshan Yadav, MD
Consultant Pathologist