

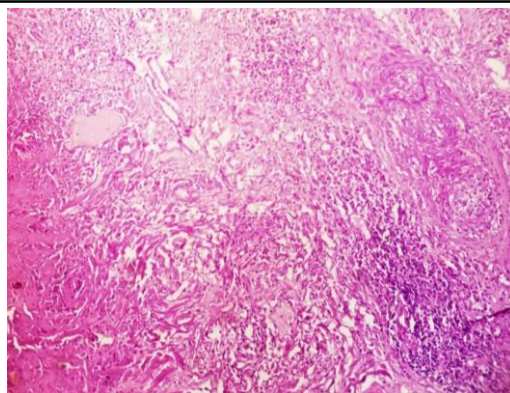
| | | | | | |
|---------------------|-----------------|--------------------|----------------|--------------------------|------------|
| Patient Name | Mr. SUMIT KUMAR | Client Name | Umkal Hospital | Specimen Received | 28/12/2020 |
| Age/Sex | 21YRS/M | | | Specimen Type | Tissue |
| Patient ID | 011912280287 | | | Collection Date | 28/12/2020 |
| Specimen ID | MOLQ/B-2265/19 | | | Report Date | 01/01/2020 |

SURGICAL PATHOLOGY REPORT

Fistula Track (Site not mentioned)

DIAGNOSIS

NON-SPECIFIC INFLAMMATION



SPECIMEN

Fistula Track (Site not mentioned)

GROSS

Received 1x1 cm grayish white tissue piece.

Microscopy

Section examined shows fibrocollagenous tissue, blood vessels with large number of inflammatory cells (Lymphocytes, plasma cells). Muscle bundle, mature adipose cells. No granuloma seen. No malignant cells seen.

Note : All biopsy specimen will be stored for 15 (fifteen) days, block and slides for 5 (five) years only from the time of receipt at the laboratory. No request, for any of the above, will be entertained after the due date.

Reference

- i) Rosai and Ackerman's Surgical Pathology.
- ii) Modern Surgical Pathology.

Gulshan Yadav, MD
Consultant Pathologist